



PATIENT
Penny Wolfe-Powell

PRESENTING CLINICAL SIGNS

History: Grade 2/6 heart murmur. BP: 114/92 (96); 157/51 (120)mmHg.
 -Current Medications Clavacillin 125mg, Carprofen 25mg, Trazadone 50mg.

SPECIES
Canine

ECHOCARDIOGRAM FINDINGS

2D, m-mode, color flow and doppler imaging is available. Mild diffuse thickening of mitral valve leaflets with minimal prolapse into the left atrial lumen. Mild eccentric mitral regurgitation with mild left atrial dilation. Normal MR velocity. Normal LV diameter with adequate myocardial function. The tricuspid valve appears normal with trace tricuspid regurgitation. Normal velocity. Normal right atrial and ventricular diameter and morphology indicating no overt evidence of pulmonary arterial hypertension. The pulmonic and aortic valves are normal in morphology and mobility. Normal pulmonic and aortic outflow velocities with laminar flow. No obvious aortic or pulmonic insufficiency. No pericardial or pleural effusion noted. No obvious cardiac masses.

BREED
Chihuahua

SEX
Female Spayed

CARDIAC CHART

AGE
6 years

WEIGHT
14.8lbs

INTERPRETED BY
Maggie Machen
Lamy, DVM, DACVIM
(Cardiology)

IMAGING PERFORMED BY
Jenna Walsh, CVT

HOSPITAL NAME
The Ark Veterinary
Clinic

REFERRING VET
Dr. Sangl

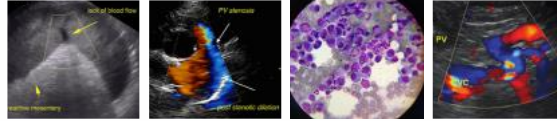
INVOICE
25818

DATE
8/16/22

CANINE CARDIAC PARAMETERS	MR VMAX (m/s)	TR VMAX (m/s)	LA/AO (Boon method)	LA/AO (Heart Base; Swe)	FS (%)	EF (%)	EPSS (cm)
NORMAL PARAMETER	4.5-5.5	<2.7	1.3	<1.6	28-40	40-100	<0.6
PATIENT	5.4	2.0	1.67	1.5	46	79	NM
CANINE CARDIAC PARAMETERS	HR (BPM)	AV VMAX (m/s)	PV MAX (m/s)	BODY WEIGHT (kg)	LA 2D short axis Base view (cm)	LVIDd Avg; 2D and m-mode short axis (cm)	LVIDs Avg; 2D and m-mode short axis (cm)
NORMAL PARAMETER	50-100	0.7-1.7	0.7-1.6	BELOW	BELOW	BELOW	BELOW
PATIENT	104	2.0		6.7	1.8	2.6	1.2
*Normal chamber parameters expressed as a mean value (SD)				3	1.27 (5.3)	2.46 (2.46)	1.36 (5.5)
BODY WEIGHT DEPENDENT PARAMETERS				5	1.40 (4.5)	2.74 (5.2)	1.60 (4.7)
Adapted from June Boon, Veterinary Echocardiography, 1998				10	1.50 (3.8)	3.27 (3.5)	2.06 (3.1)
Rishniw M and Hollis NE, J Vet Intern Med 2000; 14:429-435				15	1.83 (2.0)	3.71 (2.4)	2.43 (2.1)
Hansson et al, Vet Rad and Ultrasound 2002				20	2.02 (1.9)	4.14 (2.2)	2.80 (2.0)
Bonagura et al. Echocardiography: principles of interpretation, Vet Clin North Am 15:1177, 1995				25	2.18 (2.4)	4.48 (2.9)	3.10 (2.5)
				30	2.33 (3.3)	4.83 (3.9)	3.39 (3.4)
				35	2.48 (4.3)	5.17 (5.0)	3.69 (4.5)
				40	2.62 (5.2)	5.48 (6.1)	3.96 (5.4)
				50	2.88 (7.1)	6.07 (8.3)	4.46 (7.4)

INTERPRETATION OF THE FINDINGS & FURTHER RECOMMENDATIONS

Chronic degenerative valve disease causing mild mitral and trace tricuspid regurgitation. Lack of significant left atrial enlargement indicates the current risk for complication is low. No concurrent issues such as pulmonary hypertension are noted in this study.



PATIENT

Penny Wolfe-Powell

SPECIES

Canine

BREED

Chihuahua

SEX

Female Spayed

AGE

6 years

WEIGHT

14.8lbs

INTERPRETED BY

Maggie Machen
Lamy, DVM, DACVIM
(Cardiology)

IMAGING PERFORMED BY

Jenna Walsh, CVT

HOSPITAL NAME

The Ark Veterinary
Clinic

REFERRING VET

Dr. Sangl

INVOICE

25818

DATE

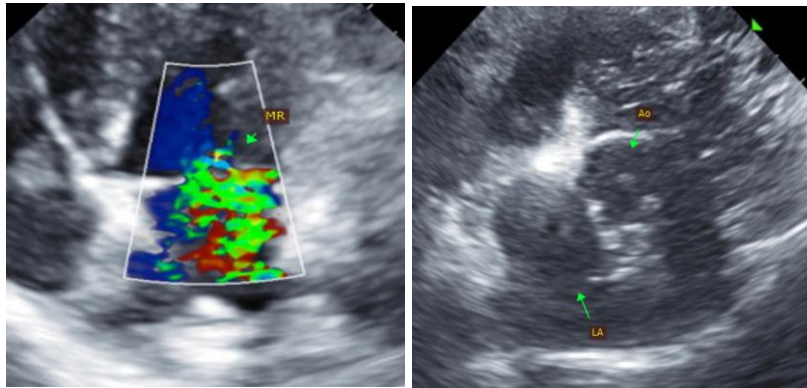
8/16/22

In an asymptomatic dog without significant left atrial enlargement, no cardiac medications are clearly indicated. Assessment of progression in the future will help predict long term prognosis, which is highly variable at this stage (B1). Omega fatty acid supplementation and mild salt restriction may be of some long-term benefit. Monitor for development of a cough, labored breathing, exercise intolerance or collapse episodes.

Anesthetic risk is considered mild if needed. Cardiac protective drug choices (opioid/benzodiazepine premedication, propofol or alfaxalone induction, isoflurane gas) are recommended. Pre-oxygenate for 5-10 minutes prior to induction. Monitor for arrhythmias, hypotension, and hypoxia both intra and post-operatively and intervene as necessary. Mild IV fluid restriction is recommended to avoid fluid overload. Avoid heart rate stimulating drugs such as atropine unless clinically indicated.

Recommend conservative monitoring with a recheck echocardiogram in 6 months, sooner if any development of clinical signs.

IMAGES



The information and recommendations provided are based on the images presented by the referring veterinarian. No evaluation can be communicated regarding pathology that was not visible in the image/video clips provided.

Thank you for this referral. This report was generated using transcription software, and minor dictation errors may be present. If the clinical or image interpretation does not parallel your findings or if I can be of any further assistance, please contact me.

Maggie Machen Lamy, DVM
Diplomate of the American College of Veterinary Internal Medicine (Cardiology)
info@sonopath.com